

Demystifying the enigma of the foreign body

A quality improvement project to improve knowledge of the appearance of commonly inhaled and swallowed foreign bodies on radiographs to enable prompt patient management.

Dr Kandise Jackson.

Dr Fiona Stephenson. Royal Oldham Hospital, Oldham. Greater Manchester, UK.

Purpose

- Foreign body inhalation and ingestion in children is a common presentation to the emergency department.
- Both are most common in the under 5 year old age group with aspiration more common in the under 3 year olds.
- Often the initial event is unwitnessed and therefore the object type unknown.
- Plain radiography is used as part of initial management and this imaging is often reviewed first line by the Emergency department team and paediatricians without radiology input.
- To enable prompt and appropriate patient management it is essential that all members of the radiology and clinical teams are aware of the imaging features of different types of foreign body.
- The visibility of a foreign body on a radiograph is determined by what the the object is made from and whether or not it is radio-opaque on imaging. Knowing which objects are radio-opaque or not is not always easy.
- A good understanding of how foreign bodies can cause pathology and how these pathologies can appear on imaging is an essential part of image interpretation.
- If accurate assessment of a hazardous foreign body is not made then this can have significant patient morbidity and risk of death.

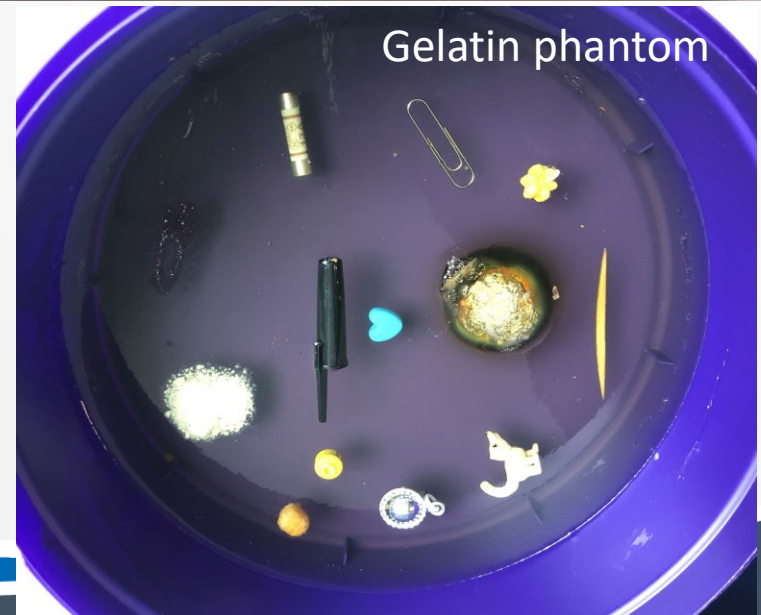We aimed to address 2 problems:

- 1- To improve recognition of various types of inhaled and swallowed foreign bodies on radiographs.**
- 2. To enable a better understanding of secondary features on imaging which must be evaluated if there is a relevant clinical history.**

To do this we made 2 phantoms; one using EpoxyTM resin and the other using gelatin.

Various foreign bodies which are easily accessible to children were embedded in these phantoms.

Radiographs of these phantoms were made using paediatric chest X-ray imaging parameters.

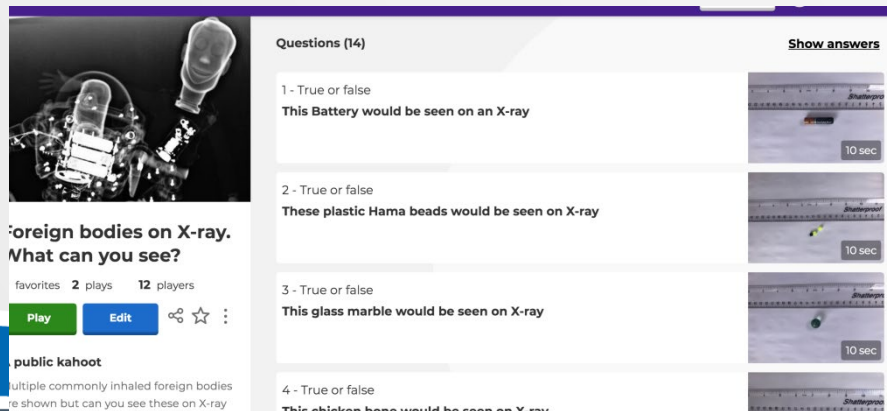


Method

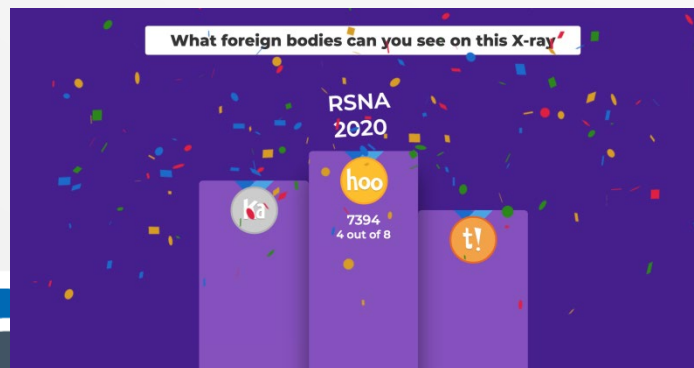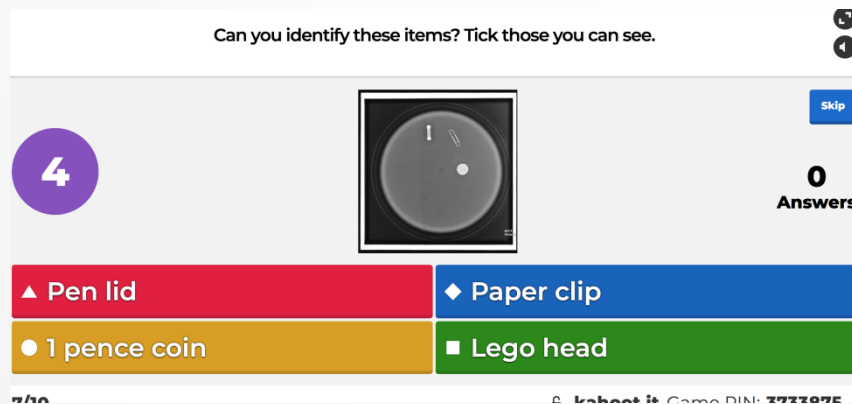
- A two part Kahoot_{TM} quiz was developed to test the base knowledge of our clinical teams which were made up of emergency and paediatric clinicians.
- The first part of this quiz showed a series of items and the question was asked if these objects would be seen on an x-ray or not.

The second part of the quiz used radiographs of the phantoms to further test knowledge. The clinicians were asked which items they could identify on X-ray.

Quiz 1



Quiz 2

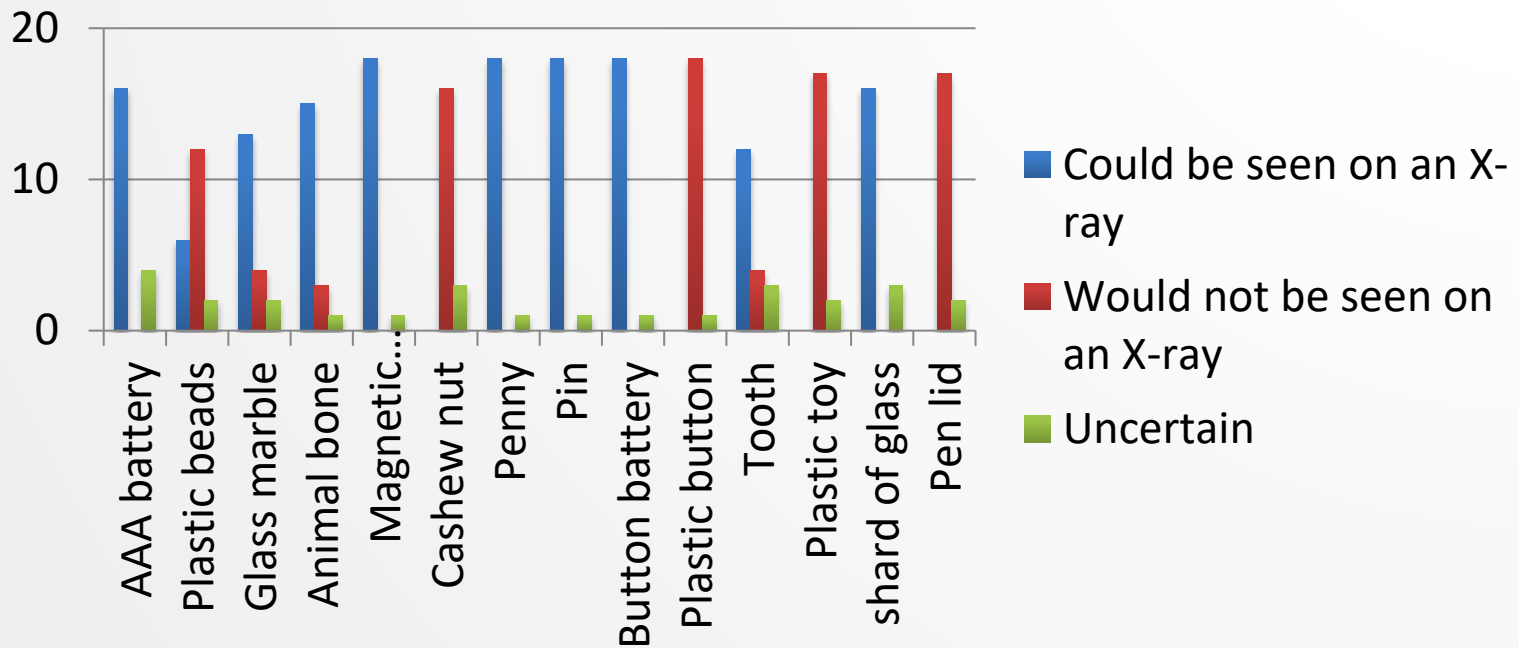


Method

- Following the two part Kahoot quiz an educational teaching session was provided to give feedback to the clinical teams; to highlight which foreign bodies were more difficult to identify on X-ray and to demonstrate this by reviewing the phantoms and the radiographs of phantoms.
- When foreign bodies could be seen, how to discriminate between different foreign bodies was discussed E.g Bilaminar and bevelled edge structure of a button battery compared to a one pence coin.
- The feedback session included teaching on how to assess X-rays for secondary features of inhalation or ingestion particularly in relation to evaluation of a suspected radiolucent foreign body.
- Results of the online quizzes and feedback forms was used to assess the baseline knowledge of clinicians, provide further education and to demonstrate that the sessions had improved knowledge.

Results

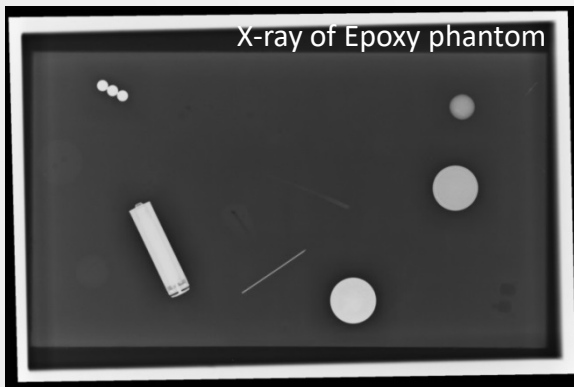
Quiz 1 asked the clinician's which items they thought could be seen on a radiograph.



Items the clinicians were confident would be seen on an X-ray were; magnetic beads, pin, penny and button battery.

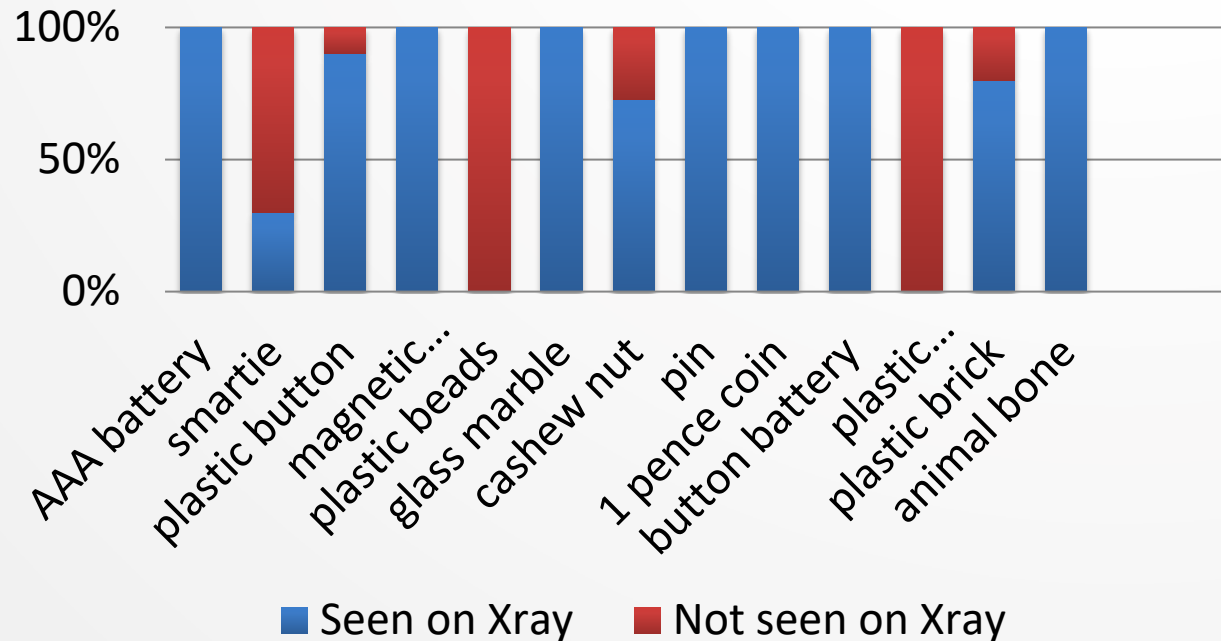
Items where there was more uncertainty were plastic beads, animal bone and tooth.

Quiz 2 asked the clinical teams which items they were able to positively identify on the radiographs of the epoxy and gelatin phantoms.



13 foreign bodies in phantom.
6 made of a radio-opaque material.
5 made of a radiolucent material but partly seen on X-ray
2 made of radiolucent material and not seen on X-ray.

Items positively identified on the X-ray of the epoxy phantom



Results

After the quizzes had been completed a radiology consultant led teaching session was provided to review the areas of inconsistency in identification of foreign bodies of X-ray.

This session also aimed to improve knowledge when assessing radiographs for secondary features of ingestion or inhalation.

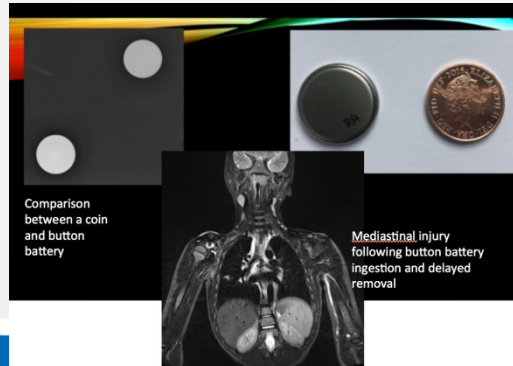Feedback from this session rated use of the quiz format 4.8/5 and the teaching session also scored highly 4.8/5.

Prior to the session clinicians rated their level of confidence in recognising features of ingested or inhaled foreign bodies on average 5.3/10 and after this session 8.3/10.



Paediatric Chest Imaging for ED

Dr Kandise Jackson
Consultant Radiologist
Royal Oldham Hospital, Northern Care Alliance



Example of slides from teaching session

- **Accurate evaluation of a foreign body following a history of ingestion or inhalation is essential to ensure prompt and appropriate patient management .**
- **Non specialist reporters are often the first line reporters of X-rays.**
- **This study used an interactive, quiz based format to review base line knowledge of the clinical teams.**
- **A follow up teaching session successfully provided an educational review to increase understanding of the characteristics of both radio-opaque and radiolucent foreign bodies and to improve the knowledge of secondary features of inhaled and aspirated foreign bodies.**
- **These sessions showed an improvement in knowledge and understanding amongst first line reporters to allow early more accurate identification of potentially lethal foreign bodies to ensure prompt treatment and optimal patient outcomes.**

References:

- 1) Foreign bodies in the gastrointestinal tract. Wyllie R .Curr Opin Pediatr. 2006;18(5):563.
- 2) A randomized clinical trial of the management of esophageal coins in children. Waltzman ML, Baskin M, Wypij D, Mooney D, Jones D, Fleisher G. Pediatrics. 2005;116(3):614.
- 3) Esophageal foreign bodies in the pediatric population: our first 500 cases. Little DC, Shah SR, St Peter SD, Calkins CM, Morrow SE, Murphy JP, Sharp RJ, Andrews WS, Holcomb GW 3rd, Ostlie DJ, Snyder CL. J Pediatr Surg. 2006;41(5):914
- 4) Management of ingested foreign bodies in children: a clinical report of the NASPGHAN Endoscopy Committee. Kramer RE, Lerner DG, Lin T, Manfredi M, Shah M, Stephen TC, Gibbons TE, Pall H, Sahn B, McOmber M, Zacur G, Friedlander J, Quiros AJ, Fishman DS, Mamula P, North American Society for Pediatric Gastroenterology, Hepatology, and Nutrition Endoscopy Committee. J Pediatr Gastroenterol Nutr. 2015;60(4):562.
- 5) Nonfatal choking-related episodes among children--United States, 2001. Centers for Disease Control and Prevention (CDC) MMWR Morb Mortal Wkly Rep. 2002;51(42):945.
- 6) WISQARS Leading causes of death reports, 1999 - 2001. National Center for Injury Prevention and Control
- 6) <https://pubs.rsna.org/doi/full/10.1148/rg.2015140287>